

An outbreak of francisellosis in wild-caught Celtic Sea Atlantic cod, *Gadus morhua* L., juveniles reared in captivity

N M Ruane¹, M Bolton-Warberg², H D Rodger³, D J Colquhoun⁴, M Geary¹,
S J McCleary¹, K O'Halloran², K Maher², D O'Keeffe², L Mirimin², K Henshilwood¹,
F Geoghegan¹ and R D Fitzgerald²

1 Fish Health Unit, Marine Institute, Oranmore, County Galway, Ireland

2 Carna Research Station, Ryan Institute, National University of Ireland, Galway, Ireland

3 Vet-Aqua International, Oranmore Business Park, Oranmore, County Galway, Ireland

4 Norwegian Veterinary Institute, Oslo, Norway

Keywords: Atlantic cod, disease, *Francisella noatunensis* subsp. *noatunensis*, wild fish.

Atlantic cod, *Gadus morhua* L., is among the most important commercial fishing species in the north-east Atlantic and from the late 1990s was considered one of the most promising species for future aquaculture development (Rosenlund & Skretting 2006; Rosenlund & Halldórsson 2007). In the last decade, production increased to over 20 000 tonnes with the majority of this coming from Norway and, to a lesser extent, Canada and Iceland. However, in recent years, farming efforts have waned and the industry has not developed in line with earlier expectations (Rosenlund & Skretting 2006). Several factors are now perceived as critical impediments to cod farming in north-western Europe, including market trade forces, technical issues and, critically, a number of biological bottlenecks such as juvenile quality (Koedijk *et al.* 2010), early sexual maturation (Imsland *et al.* 2013) and certain disease conditions (Samuelson *et al.* 2006). One of these diseases, francisellosis, has emerged as a serious issue for farmed cod production (Birkbeck, Feist & Verner-Jeffreys

2011; Colquhoun & Duodu 2011). Francisellosis in cod is a systemic granulomatous inflammatory disease which is often chronic in nature and is characterized by numerous white nodules clearly visible on the internal organs. The disease is caused by *Francisella noatunensis* subsp. *noatunensis* (Mikalsen *et al.* 2007; Ottem *et al.* 2009), a non-motile, Gram-negative, aerobic, intracellular coccobacilli which was first reported in farmed Atlantic cod in Norway in 2004 (Nylund *et al.* 2006; Olsen *et al.* 2006).

As part of a nationally funded project (EIR-COD), eggs of different family groups (full and half-sibs) have been collected annually since 2008, from wild-caught cod broodstock in the Celtic Sea. In March 2009, 608 juvenile cod (~100 g) were collected via trawl capture from a nursery area in the Waterford Estuary on the south coast of Ireland (grid reference: Lat 52°14'52N; Long 6°59'26W). A large sample ($n = 259$) of the catch was immediately culled and stored-frozen for later examination (150 of these fish subsequently tested negative for *Francisella* sp. by real-time PCR). The remaining fish ($n = 349$) were then transferred overland (300 km in 5 h) in aerated tanks to Carna Research Station (NUIG), Co. Galway. At the station, the biomass was distributed evenly among three glass reinforced plastic (GRP) tanks (2 m diameter, 0.8 m depth) each with 1700 L

capacity. Water was supplied to holding tanks via a flow-through ambient system, with both intake and effluent being filtered and UV-sterilized. Temperature was measured and recorded using deployed Tiny Tags[®] with means ranging from 8 °C in March to 18 °C in July. Oxygen concentration was monitored twice daily in the outlet of each tank and maintained at >80% saturation. Dark polythene covers were placed over tanks to minimize disturbance to fish during this initial acclimation phase. In addition to the wild-caught juveniles being held at this time, cod from 2 year-classes (2008 1+ and 2009 0+) were also held in the same facility. These fish had been collected as eggs from wild broodstock during Marine Institute surveys in the Celtic Sea.

Initial mortality occurred following capture and transfer to holding tanks and during early acclimation, but this abated after the first 2 weeks, and the number remaining by May 21 was 302 (86.8% survival). On that first sampling, it was apparent that the overall mean weight of fish had not increased appreciably since capture (from ~100 to 123 g), and there was a considerable size disparity in the stocks. Hence, they were sorted into three arbitrary size grades: small ($n = 120$; mean 71.7 g), medium ($n = 134$; mean 131.1 g) and large ($n = 48$; mean 249.1 g). Mortalities continued to occur in all three size grades over the remaining weeks (Fig. 1). Overall, 50% mortality was recorded from initial stocking until the final cull with significantly greater mortalities in the small grade ($\chi^2 = 9.75$; $df = 2$; $P \leq 0.01$).

On 18 August 2009, 18 of the wild-caught juvenile stock were sampled as part of a

surveillance inspection under EU Directive 2006/88/EC. *Aeromonas salmonicida* was isolated from a gill swab on Columbia blood agar supplemented with 2% salt (CBA+), and a *Vibrio* sp. and *Pseudomonas* sp. were isolated on CBA+, seawater agar (SWA) and cysteine heart agar (CHA) plates from kidney swabs. All agar plates were produced commercially (Fannin Ltd), and the bacteria were identified by standard primary (including vibriostatic disc 0129 (Oxoid)) and secondary biochemical tests (API 20E, API NE, API ZYM; Biomerieux). No virus was isolated from three separate pools of tissues (heart, kidney and spleen) tested using BF-2 and EPC cell lines. The presence of significant clinical pathologies consistent with francisellosis, such as extensive granulomatous, white nodules on the surface of the major internal organs, was evident in a large proportion (~61%) of the sampled fish (Fig. 2a,b). During the final cull, it was observed that, in severe cases, these granulomas presented as enlarged ascites on the surface of the spleen (Fig. 2b). Three fish were examined by histopathology, and after initial haematoxylin and eosin staining, there was evidence of a systemic bacterial infection causing necrotic-centred granulomas in the internal organs of each fish (Fig. 2c). Further staining showed the presence of intracellular bacteria that were Ziehl-Nielsen negative and Giemsa positive. *Francisella noatunensis*-specific immunohistochemistry, as described by Zerihun *et al.* (2011), was performed on paraffin-embedded sections resulting in abundant positive staining of bacterial cells within the granulomatous tissues (Fig. 2d). The three tissue homogenates used for virological testing were also

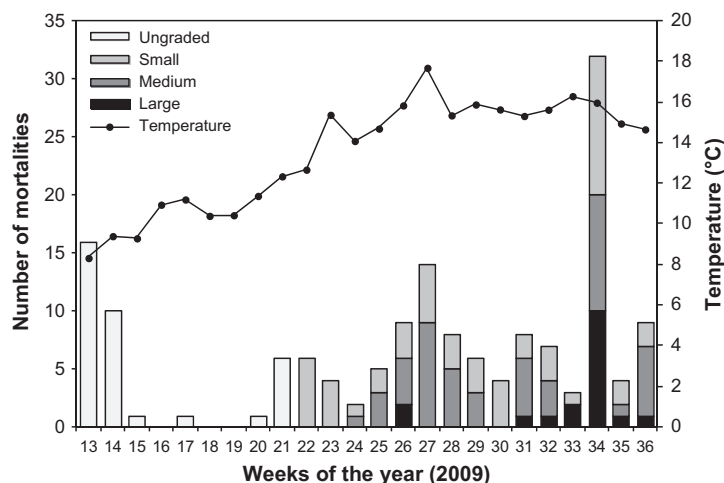


Figure 1 Weekly mortalities in wild-caught Atlantic cod juveniles and mean water temperature in 2009 at Carna Research Station. Juveniles were graded into three size groups in week 21 and final culling took place in week 37.

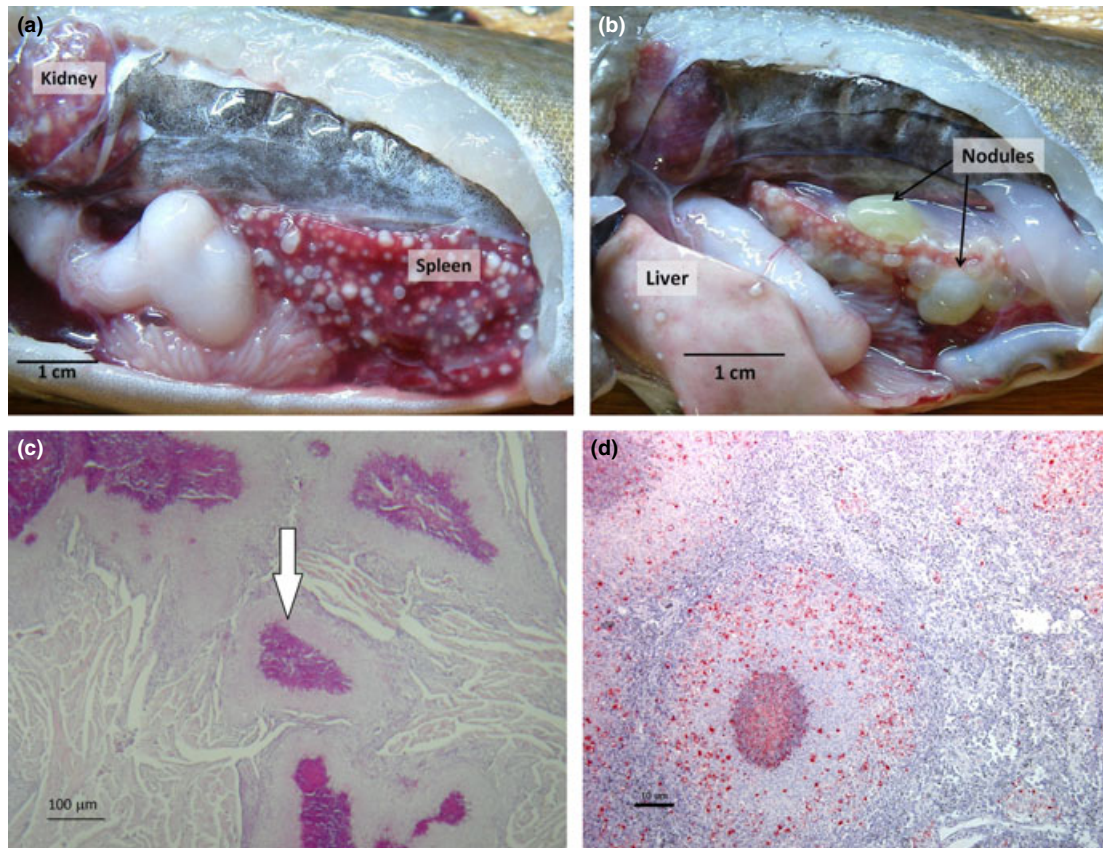


Figure 2 Gross clinical appearance on autopsy (a,b) showing characteristic multiple granulomas (white nodules) typical of francisellosis on the surface of the kidney, spleen and liver from infected Atlantic cod. In some cases, enlarged, fluid-filled nodules were evident on the spleen (b). Heart tissue stained by haematoxylin and eosin showing multiple necrotic-centred granulomas (c) and immunostaining (dark dots) with *Francisella*-specific antibody around granulomas in the spleen (d).

used to screen for *Francisella* sp. by real-time RT-PCR using a specific primer set and probe amplifying a region of the outer membrane protein FopA (Ottem *et al.* 2008). Total RNA was extracted using the RNeasy Mini Kit (Qiagen), and a one-step real-time RT-PCR was then carried out using the Platinum[®] Quantitative RT-PCR ThermoScript[™] system (Applied Biosystems). The reaction was performed on the ABI 7500 real-time PCR system (Applied Biosystems), and all three tissue homogenate pools tested positive. Cod elongation factor 1 α (ELF-1 α) was used as an internal process control (Olsvik *et al.* 2006), and *F. noatunensis* subsp. *noatunensis* NCIMB 14265^T, isolated from Norwegian cod, was used as a positive control.

Follow-up sampling took place on 10 and 11 September 2009 with the aim of isolating *Francisella noatunensis* from the infected wild-caught fish

and also to screen the other year-classes within the facility. Therefore, kidney swabs taken from five infected wild-caught fish were plated onto CHA plates supplemented with 10% vancomycin and incubated at 22 °C as standard. This resulted in the growth of pure off-white, smooth convex colonies on all inoculated plates. The bacteria were found to be Gram-negative cocci, non-motile, oxidase and catalase positive and only grew on CHA plates with the best growth observed at 22 °C, based on counting bacterial colonies. No reaction with the standard secondary biochemical tests occurred; however, the API ZYM test kit indicated that the isolate was esterase, esterase lipase, acid phosphatase and naphthol-AS-biphosphohydrolase positive.

To confirm the identity of the bacterium, a partial sequencing of the 16S ribosomal RNA gene using universal eubacteria primers (Lane *et al.*

Table 1 An overview of the health screening schedule of the various Atlantic cod stocks at Carma Research Station upon diagnosis of francisellosis

Sample date (week no.)	Sample ref	Fish stock (sample No.)	Facility	Gross pathology	Histology	Virology (BF-2 and EPC)	Bacteriology (various media)	Molecular qPCR	Notes
18 August 09 (week 34)	F/118/09	Wild-caught Juv. (n = 18)	Nursery	61% (11/18) with extensive granulomas on internal organs	Systemic bacterial infection evident: <i>Rickettsia</i> -like bacteria, possibly <i>Francisella</i>	Negative for VHS, IHN and IPN	<i>Aeromonas</i> , <i>Vibrio</i> and <i>Pseudomonas</i> spp. isolated	Three pooled samples (100%) all positive for <i>Francisella</i>	General Vet. Surveillance Inspection of wild-caught stocks
11 September 09 (week 37)	F/134/09	Wild-caught Juv. (n = 5)	Nursery	–	–	–	Isolated <i>Francisella noatunensis</i> subsp. <i>noatunensis</i>	–	Wild-caught stock sampled solely for bacteriology
Cull (week 37)	–	Wild-caught Juv. (n = 147)	Nursery	86% (126/147) granulomas on internal organs	–	–	–	–	–
10 September 09 (week 37)	F/136/09	2008 reared Cohort (n = 60)	Nursery	12% (7/60) with extensive granulomas on internal organs	Systemic bacterial infection evident: presumptive diag. <i>Francisella</i>	Negative for VHS, IHN and IPN	Isolates: sequenced similarity (98%) to <i>Vibrio ichthyenteri</i>	46.6% (28/60) samples tested positive for <i>Francisella</i>	This 2008 reared stock were housed with wild-caught fish for entire time.
10 September 09 (week 37)	F/137/09	2009 reared Cohort (n = 90)	Nursery	No clinical signs seen on autopsy	–	Negative for VHS, IHN and IPN	Isolates: sequenced similarity (98%) to <i>Vibrio ichthyenteri</i>	All samples tested negative for <i>Francisella</i>	Moved in July (week 32) to Nursery for feed experiment
10 September 09 (week 37)	F/135/09	2009 reared Cohort (n = 150)	Hatchery	No clinical signs seen on autopsy	–	Negative for VHS, IHN and IPN	Isolates: sequenced similarity (98%) to <i>Vibrio ichthyenteri</i>	All samples tested negative for <i>Francisella</i>	Held in Hatchery area on a 'closed' RAS unit
16 September 09 (week 38)	F/140/09	Commercial farm stocks (n = 150)	Sea site	No clinical signs seen on autopsy	No abnormalities detected	Negative for VHS, IHN and IPN	Isolates: sequenced similarity (98%) to <i>Vibrio ichthyenteri</i>	All samples tested negative for <i>Francisella</i>	Cod, ex-Carma, being reared on an offshore farm
19 and 20 October 09 (week 43)	F/158/09 F/160/09	Wild-caught Juv. (n = 150)	Estuary	No clinical signs seen on autopsy	No abnormalities detected	Negative for VHS, IHN and IPN	No significant bacterial fish pathogens were isolated	All samples tested negative for <i>Francisella</i>	Wild-caught cod juveniles frozen on capture in 24 March 2009

1985; Weisburg *et al.* 1991): 8F (5'-AGAGTTTG ATCCTGGCTCAG-3') and 536R (5'-GWATTA CCGCGGCKGCTG-3') was performed on three isolates. Partial sequences were also obtained from the following housekeeping genes: groEL (889 bp), shdA (486 bp), rpoB (494 bp) and pgm (655 bp) using primers described by Mikalsen *et al.* (2007) and putA (491 bp) using primers described by Ottem *et al.* (2009). BLAST analysis revealed 100% sequence identity with *Francisella noatunensis* subsp. *noatunensis* isolated from farmed Atlantic cod in Norway for all sequenced loci.

The two other Atlantic cod year-classes held at Carna (2008 1+ and 2009 0+) were sampled for virology, bacteriology, histopathology and molecular screening by real-time RT-PCR as described above. No virus was isolated from any of the samples, and a *Vibrio* sp. was isolated from a number of fish from both year-classes (sequencing of the partial 16S rRNA gene as described above showed that the bacteria had 98% similarity to *Vibrio ichthyoenteri*). Seven of the 60 2008 year-class fish sampled had visible signs of disease (granulomas), and histopathological examination indicated a systemic bacterial infection. There were no signs of disease in the 2009 year-class fish. Kidney tissues taken for molecular analysis during this testing showed 0/90 2009 year-class and 28/60 2008 year-class tested positive for *Francisella* sp. Due to the occurrence of granulomas and positive molecular results in the 2008 1+ year-class Atlantic cod, it was decided to cull both year-classes for quarantine purposes. When culled, it was found that ~7% of the 2008 1+ fish ($n = 337$; mean 413.2 g) and 0% of the 2009 0+ fish ($n = 440$; mean 6.1 g) showed visible signs (white nodules) of the disease. It is noteworthy that the older year-class had been present in the nursery building for the entire duration of the acclimation process with the wild-caught fish, while the younger fish had only been transferred into that area in July 2009. When the wild-caught fish were culled, visible signs of disease were noted in 85% of those fish. Other Atlantic cod groups from the research facility were also tested for *Francisella*, and all details are shown in Table 1.

The use of wild Atlantic cod as broodstock for supplementing the production of juveniles is a common practice (Rosenlund & Halldórsson 2007). A major disadvantage of this can be the accidental introduction of pathogens. Although initial samples culled at capture were negative, in

this case it is likely that the cause of the infection was the wild fish themselves. An alternative explanation is that the intake water was the source of infection. However, this water was filtered and UV-irradiated before entering the system, and given the fact that there have not been any further outbreaks since 2009, suggests that this is unlikely. Characterization of the causative agent (Mikalsen *et al.* 2007; Ottem *et al.* 2007) and development of sensitive diagnostic methods, both molecular based and culture, have led to a greater awareness of francisellosis and its occurrence in farmed and wild fish (Colquhoun & Duodu 2011). There is also evidence that the bacterium is prevalent in wild Atlantic cod along the west coasts of Sweden and Norway (Ottem *et al.* 2008; Colquhoun & Duodu 2011). In the 1980s, there were reports of a visceral granulomatous disease in cod from the North Sea of unknown aetiology. A study using archived formalin-fixed paraffin-embedded tissue blocks of Atlantic cod sampled from the southern North Sea in 1988 showed that *F. noatunensis* was the causative agent of this disease (Zerihun *et al.* 2011). The present study provides, by extending its recognized distribution range into the Celtic Sea, further evidence that *F. noatunensis* subsp. *noatunensis* is widespread in the north-east Atlantic. It is clear that this bacterium will, unless a vaccine is developed, continue to threaten the future development Atlantic cod farming in a number of northern European countries.

Acknowledgements

The authors would like to acknowledge the financial support of the EIRCOD project, funded under the Sea Change initiative with the support of the Marine Institute and the Marine Research Sub-programme of the National Development Plan 2007 – 2013 and co-funded by the European Regional Development Fund. The authors generously acknowledge the assistance of all staff at Carna Research Station and those of the Fish Health Unit, Marine Institute. Dr. Adam Zerihun, Norwegian Veterinary Institute, is also acknowledged for his assistance with the immunohistochemistry.

References

- Birkbeck T.H., Feist S.W. & Verner-Jeffreys D.W. (2011) *Francisella* infections in fish and shellfish. *Journal of Fish Diseases* **34**, 173–187.

- Colquhoun D.J. & Duodu S. (2011) *Francisella* infections in farmed and wild aquatic organisms. *Veterinary Research* **42**, 47.
- Imsland A.K., Hanssen H., Foss A., Vikingstad E., Roth B., Bjørnevik M., Powell M., Solberg C. & Norberg B. (2013) Short-term exposure to continuous light delays sexual maturation and increases growth of Atlantic cod in sea pens. *Aquaculture Research* **44**, 1665–1676.
- Koedijk R.M., Folkvord A., Foss A., Pittman K., Stefansson S.O., Handeland S. & Imsland A.K. (2010) The influence of first-feeding diet on the Atlantic cod *Gadus morhua* phenotype: survival, development and long-term consequences for growth. *Journal of Fish Biology* **77**, 1–19.
- Lane D.J., Pace B., Olsen G.J., Stahl D.A., Sogin M.L. & Pace N.R. (1985) Rapid determination of 16S ribosomal RNA sequences for phylogenetic analyses. *Proceedings of the National Academy of Sciences USA* **82**, 6955–6959.
- Mikalsen J., Olsen A.B., Tengs T. & Colquhoun D.J. (2007) *Francisella philomiragia* subsp. *noatunensis* subsp. nov., isolated from farmed Atlantic cod (*Gadus morhua* L.). *International Journal of Systematics and Evolutionary Microbiology* **57**, 1960–1965.
- Nylund A., Ottem K.F., Watanabe K., Karlsbakk E. & Krossøy B. (2006) *Francisella* sp. (Family Francisellaceae) causing mortality in Norwegian cod (*Gadus morhua*) farming. *Archives of Microbiology* **185**, 383–392.
- Olsen A.B., Mikalsen J., Rode M., Alfjorden A., Hoel E., Straum-Lie K., Haldorsen R. & Colquhoun D.J. (2006) A novel systemic granulomatous inflammatory disease in farmed Atlantic cod, *Gadus morhua* L., associated with a bacterium belonging to the genus *Francisella*. *Journal of Fish Diseases* **29**, 307–311.
- Olsvik P.A., Kristensen T., Waagbø R., Tollefsen K.E., Rosseland B.O. & Toften H. (2006) Effects of hypo- and hyperoxia on transcription levels of five stress genes and the glutathione system in liver of Atlantic cod *Gadus morhua*. *Journal of Experimental Biology* **209**, 2893–2901.
- Ottem K.F., Nylund A., Karlsbakk E., Friis-Møller A.F. & Krossøy B. (2007) Characterization of *Francisella* sp., GM2212, the first *Francisella* isolate from marine fish, Atlantic cod (*Gadus morhua*). *Archives of Microbiology* **187**, 343–350.
- Ottem K.F., Nylund A., Isaksen T.E., Karlsbakk E. & Bergh Ø. (2008) Occurrence of *Francisella piscicida* in farmed and wild Atlantic cod, *Gadus morhua* L., in Norway. *Journal of Fish Diseases* **31**, 525–534.
- Ottem K.F., Nylund A., Karlsbakk E., Friis-Møller A.F. & Kamaishi T. (2009) Elevation of *Francisella philomiragia* subsp. *noatunensis* Mikalsen *et al.* (2007) to *Francisella noatunensis* comb. nov. [syn. *Francisella piscicida* Ottem *et al.* (2008) syn. nov.] and characterization of *Francisella noatunensis* subsp. *orientalis* subsp. nov., two important fish pathogens. *Journal of Applied Microbiology* **106**, 1231–1243.
- Rosenlund G. & Halldórsson Ó. (2007) Cod juvenile production: research and commercial developments. *Aquaculture* **268**, 188–194.
- Rosenlund G. & Skretting M. (2006) Worldwide status and perspective on gadoid culture. *ICES Journal of Marine Science* **63**, 194–197.
- Samuelsen O.B., Nerland A.H., Jørgensen T., Schröder M.B., Svåsand T. & Bergh Ø. (2006) Viral and bacterial diseases of Atlantic cod *Gadus morhua*, their prophylaxis and treatment: a review. *Diseases of Aquatic Organisms* **71**, 239–254.
- Weisburg W.G., Barns S.M., Pelletier D.A. & Lane D.J. (1991) 16S ribosomal DNA amplification for phylogenetic study. *Journal of Bacteriology* **173**, 697–703.
- Zerihun M.A., Feist S.W., Bucke D., Olsen A.B., Tandstad N.M. & Colquhoun D.J. (2011) *Francisella noatunensis* subsp. *noatunensis* is the aetiological agent of visceral granulomatosis in wild Atlantic cod *Gadus morhua*. *Diseases of Aquatic Organisms* **95**, 65–71.